

# Buccal Bone Resorption Around Posterior Implants After Surgery: A 1-Year Prospective Study

Toshio Takuma, DDS<sup>1,2</sup>/Keiji Oishi, DDS, PhD<sup>3</sup>/Tomofusa Manabe, DT<sup>2</sup>/  
Satoshi Yoneda, DDS, PhD<sup>4</sup>/Toshihiko Nagata, DDS, PhD<sup>5</sup>

**Purpose:** This prospective study aimed to examine postoperative dimensional changes in the buccal bone and mucosa around single-stage implants placed in the posterior region. **Materials and Methods:** The dimensions of peri-implant tissue around screw-type implants placed in the posterior region were examined at surgery (baseline) and 6 months and 1 year after surgery. The lateral contour of the buccal bone and mucosa was horizontally measured at five vertical heights at 1-mm intervals (+1 to -3 mm from the implant platform) using custom-designed instruments. Bone resorption on the proximal sides was assessed on radiographs. Mucosal recession was measured on plaster casts of the dentition. **Results:** Sixty-six implants placed in 30 patients were examined. All implants were clinically osseointegrated and stable throughout the study period. The buccal bone exhibited horizontal resorption throughout the study period, even at the most apical height measured. Assessed at each height, thicker bone (> 2 mm thick) tended to exhibit horizontal resorption during the first 6 months after surgery. However, the bone resorbed horizontally by approximately 0.4 mm during the final 6 months, irrespective of its contour. Vertical resorption of the buccal marginal bone was approximately 1 mm during the period from 6 months to 1 year. The bone-retaining group at the 1-year time point was found to have thicker bone walls at baseline compared with the bone-loss group. The thickness of the buccal mucosa showed little change. There was no obvious correlation between buccal bone resorption and mucosal recession. **Conclusions:** The buccal bone exhibited both horizontal and vertical resorption over the year after surgery. The initial contour of the bone was significantly associated with bone retention or loss at 1 year. However, mucosal recession was not directly affected by buccal bone resorption. INT J ORAL MAXILLOFAC IMPLANTS 2014;29:634-641. doi: 10.11607/jomi.3018

**Key words:** buccal bone resorption, dental implants, mucosal recession, prospective study

Maintenance of peri-implant tissue has been an important issue in the field of implant dentistry<sup>1,2</sup> ever since it was anticipated that osseointegration was

highly likely. Maintenance of the level and shape of peri-implant tissue facilitates easy cleaning of the fixed prostheses, contributing to maintenance of marginal tissue health. The health and stability of peri-implant tissue are key factors affecting the longevity of implants.<sup>3,4</sup> Proper shape is also related to the esthetics of implant-based prostheses. However, alveolar bone tends to exhibit both vertical and horizontal resorption after tooth extraction.<sup>5-7</sup> In addition, it is well-known that marginal bone loss around implants is radiographically observed soon after abutment placement.<sup>1,8,9</sup> These trends may affect the level and shape of peri-implant tissue.

The shape of peri-implant tissue may be closely associated with the morphology of the underlying alveolar bone.<sup>10</sup> Marginal bone loss that has been reported on the proximal side<sup>11,12</sup> was also anticipated on the buccal side during the first 6 months after implant treatment. However, the shape and thickness of the buccal bone cannot be examined on a conventional radiograph. Although some researchers used computed tomography (CT) to assess the buccal bone

<sup>1</sup>Graduate student, Department of Periodontology and Endodontology, Institute of Health Biosciences, The University of Tokushima Graduate School, Japan.

<sup>2</sup>Private Practice, Kagawa, Japan.

<sup>3</sup>Associate Professor, Department of Periodontology and Endodontology, Institute of Health Biosciences, The University of Tokushima Graduate School, Japan.

<sup>4</sup>Assistant Professor, Department of Periodontology and Endodontology, Institute of Health Biosciences, The University of Tokushima Graduate School, Japan.

<sup>5</sup>Professor and Head, Department of Periodontology and Endodontology, Institute of Health Biosciences, The University of Tokushima Graduate School, Japan.

**Correspondence to:** Dr Keiji Oishi, Department of Periodontology and Endodontology, Institute of Health Biosciences, The University of Tokushima Graduate School, 3-18-15 Kuramoto-cho, Tokushima 770-8504, Japan. Fax: +81-88-633-7345. Email: ohishik@tokushima-u.ac.jp

©2014 by Quintessence Publishing Co Inc.

thickness around implants,<sup>13,14</sup> the accuracy of this technique was limited because of artifacts caused by the implants.<sup>15,16</sup> In another study,<sup>17</sup> the critical thickness required to maintain the buccal bone wall was proposed on the basis of a comparison between the thickness in placement surgery and that in uncovering surgery. The study, however, did not examine the progress of changes after uncovering surgery. Therefore, dimensional changes in the buccal bone around implants have not been examined in detail because of the lack of suitable measurement techniques.

To predict dimensional changes in peri-implant tissue after surgery, it is important to understand the general progress of dimensional changes after treatment. This includes evaluation of the extent of horizontal and vertical dimensional changes in the buccal bone after surgery as well as the thickness of buccal bone required around implants to prevent its resorption after surgery. To address these clinical questions, the authors created a set of instruments to precisely measure the lateral contour of the buccal bone and soft tissue and planned a 1-year prospective cohort study to assess dimensional changes in the buccal peri-implant tissue in patients who received single-stage implants.

## MATERIALS AND METHODS

### Patient Selection

The present study was conducted in the Department of Periodontology at Tokushima University Hospital (Tokushima, Japan) and Takuma Dental Clinic (Marugame, Japan) between April 2009 and June 2011. The research protocol was approved by the Ethics Committee of Tokushima University Hospital (Approval No. 819) in accordance with the 1975 Helsinki Declaration as revised in 2000. Consecutive patients visiting the clinics for implant treatment were recruited for this study. Inclusion criteria were as follows: (1) age over 20 years, (2) planned treatment using posterior implants without ridge augmentation, and (3) implant sites allowed to heal for more than 3 months after tooth extraction. Exclusion criteria were as follows: (1) poor oral hygiene and uncontrolled periodontal disease; (2) present or past history of smoking<sup>18</sup>; (3) presence of systemic diseases such as diabetes and osteoporosis; (4) pregnancy; and (5) history of chemotherapy, irradiation therapy, or long-term steroid treatment. All participants provided written informed consent prior to entry into this study.

### Treatment Protocol

All patients received oral hygiene instructions and adequate periodontal treatment for the remaining teeth

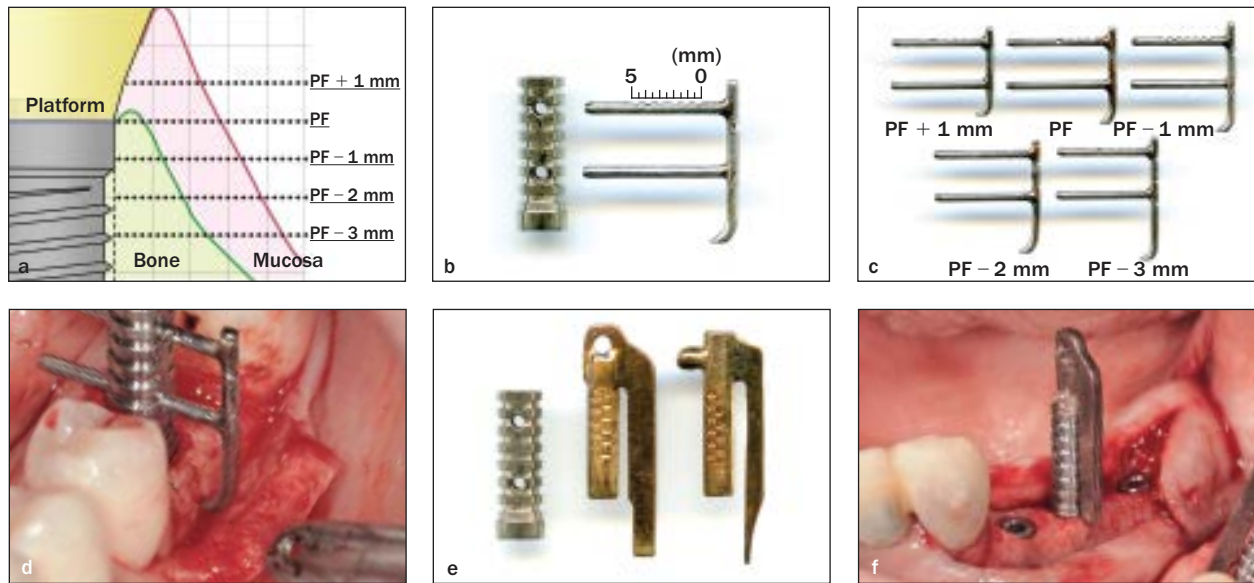
before implant treatment. The precise position and angulation of implants were designed on CT images of jawbones using image analysis software (SimPlant, Materialize). The vertical axis of the implant fixture was approximately in the center of the alveolar bone and final superstructures. The interimplant distance and implant-tooth distance were greater than 3 and 2 mm, respectively.<sup>19</sup>

All surgical procedures were performed by a single surgeon (TT). Under local anesthesia, full-thickness mucosal flaps were elevated, and implant holes were drilled as planned using prefabricated surgical templates. Implants measuring 4.0 mm in diameter (dual acid-etched Osseotite NT, Biomet/3i)<sup>12</sup> were placed in the planned positions such that their platforms were approximately level with the bone surface. Healing abutments were screwed onto the implants, and wounds were sutured. This point represented the baseline of this study.

The surgical sites in the maxilla and mandible were allowed to heal for 4 and 3 months, respectively, without loading. Implants were loaded with provisional restorations after the implant stability quotient (ISQ) values were checked using Osstell Mentor (Osstell AB). All patients received screw-retained definitive restorations 6 months after surgery. As part of the maintenance program, the patients were recalled 1 year after surgery to check and clean the implants. The modified gingival index (mGI) and modified plaque index (mPI) were recorded at 6 months and 1 year after surgery. The morphology of the buccal peri-implant tissue was evaluated at baseline and 6 months and 1 year after surgery.

### Morphologic Evaluation of the Alveolar Bone

The lateral contour of the buccal bone was measured at the five vertical heights defined with reference to the implant platform (PF): PF + 1 mm, PF, PF – 1 mm, PF – 2 mm, and PF – 3 mm (Fig 1a). These heights were 1 mm coronal to the platform, at the platform level, and 1 mm, 2 mm, and 3 mm apical to the platform, respectively. The height coronal to the platform (PF + 1 mm) was measured to check the growth of the buccal bone. At baseline, ie, just after implant placement, the lateral contour of the buccal bone was directly measured using the authors' original handmade device (Figs 1b and 1c). The base of the instrument was fixed on the implant with a screw to direct the guide holes in the buccal direction. Next, a horizontal ruler component was inserted into the guide holes from the buccal side until resistance was encountered against the buccal bone (Fig 1d). These rulers were graduated in 0.5-mm increments on the upper horizontal bar (see Fig 1b). The 0 mark appeared on the guide hole of the base of the horizontal bar when the apical tip was placed on the lateral surface of the implants. There-



**Figs 1a to 1f** Evaluation of bone morphology during surgery. (a) Measurements were obtained at five heights. (b) Device for measuring the lateral contour of the buccal bone: (left) base component, (right) ruler component. (c) Ruler components for the different heights. (d) The base was fixed onto an implant with a screw. The ruler component was then inserted into guide holes on the base to measure the contour of the buccal bone. (e) Devices to measure the vertical height of bone around the implants, left to right: base component, probe for measuring buccal walls, probe for measuring mesial/distal walls. (f) A probe was vertically inserted into a fixed base to measure the vertical height of the buccal, mesial, and distal bone walls.

fore, the device could measure the distance between the buccal bone surface and lateral implant surface in a horizontal direction. To measure the bone contour at the five different heights, the authors used five ruler components of different lengths (see Fig 1b). The scale on the ruler could be accurately read under a surgical microscope (Universa 300, Mölar-Wedel International) at 8× to 16× magnification. Similarly, the vertical distance between the bone around the implants and the platform was measured using the same base and vertical ruler components (Fig 1e). The ruler was inserted from the top of the base to probe the mesial, distal, and buccal walls of the bone around the implants (Fig 1f), and the vertical distance between the bone and platform was measured on the scale on the ruler using a surgical microscope. If the bone level was apical to the platform, it was expressed as a negative value.

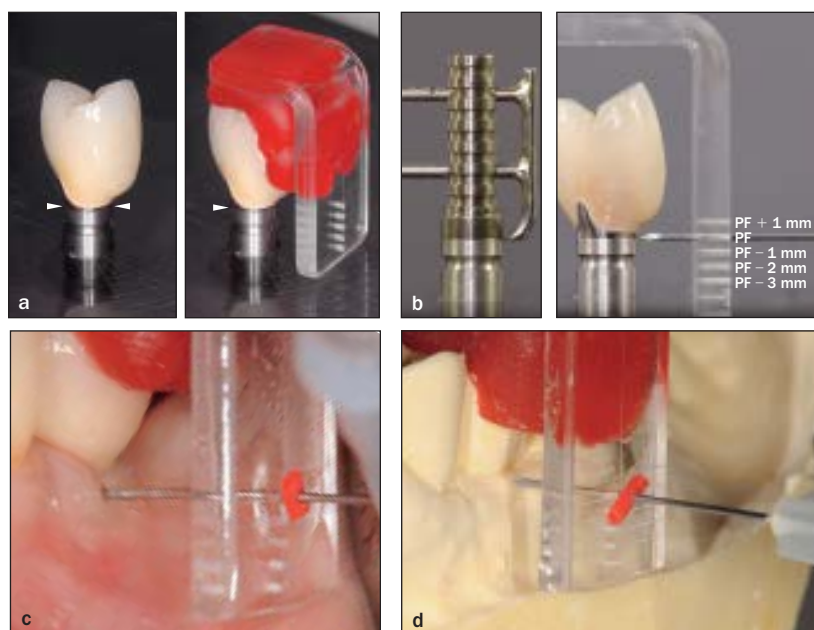
At the 6-month and 1-year time points, the contour of the buccal bone was measured using an individual guide fixed onto each prosthesis (Fig 2a). To prefabricate the acrylic guide, the definitive prostheses were fixed with a screw on an implant analog at a 4-mm height from the base before actual placement on the implant. The acrylic guides had a buccal plate that was parallel to the implant axis and contained five 0.45-mm-diameter holes. Starting 1 mm from the bottom, the five holes were aligned vertically at 1-mm intervals such that each hole was at one of the

five defined heights from PF + 1 mm to PF - 3 mm (Fig 2b). Self-curing resin was inserted between the acrylic guide and the prosthesis so that the guide was firmly fixed on the occlusal and buccal surfaces of the prosthesis (see Fig 2a). The distance between the implant surface and the buccal plate of the guide was measured using a precise caliper and recorded. After the prostheses were fixed onto the implants, sterilized individual guides were seated on their crowns. Under local anesthesia, a 27-gauge sterile needle (0.40-mm diameter) with a rubber stopper was inserted into each hole to sound the bone surface at each vertical height (Fig 2c). The distance between the needle tip and the rubber stopper was measured using a scale that was read under a microscope. The distance between the implant surface and buccal bone surface at each height was then calculated from these measured values. A calculated value of more than 0.1 mm indicated the presence of buccal bone around the implant.

Vertical heights of the most coronal part of the buccal bone at 6 months and 1 year after surgery were estimated from the buccal bone contour. For example, when bone contours were 0 and 0.5 mm at PF and PF - 1 mm, respectively, the height was estimated to be between 0 and -1 mm.

All measurements were performed by a single surgeon (TT). Consistency between repeated measurements was within 0.2 mm in a preliminary study.

**Fig 2** Measurement of buccal bone and soft tissue contour after crown placement. (a) An acrylic guide with five holes was prefabricated to fit the crown at a parallel orientation to the implant axis. Arrowheads indicate the location of the platform. (b) Five holes were created on the guide at the same heights from PF + 1 mm to PF - 3 mm. (c) Bone sounding was performed under local anesthesia using a 27-gauge needle inserted through a hole at each height. (d) The contour of soft tissue was probed on a plaster cast using the same guide.



### Measurement of Horizontal Thickness and Vertical Recession of the Buccal Mucosa

In order to measure the horizontal thickness of the buccal mucosa at 6 months and 1 year after surgery, impressions of the prostheses with alveolar ridges were obtained to create plaster casts. The same guides used to measure bone contour were seated on the cast tooth crowns, and the cast surface was probed with a 27-gauge needle (Fig 2d). The distance between the implant surface and alveolar surface at each vertical height was calculated from the measured values. The bone contour was subtracted from the distance, and the resulting values were estimated to represent the horizontal thickness of the buccal mucosa.

To assess vertical recession of the buccal mucosa after prosthetic treatment, the vertical distance from the top of the crown to the margin of the buccal mucosa was measured on plaster casts prepared 6 months and 1 year after surgery. The extent of recession was calculated from these measurements.

### Radiographic Examination

To examine marginal bone resorption on the proximal sides, periapical radiographs were obtained using the paralleling technique with a Rinn film holder (Dentsply-Rinn) and personalized bite blocks. All standardized periapical radiographs were scanned and digitized using an image scanner (ES-2200, Epson) at 720 dpi resolution. On these images, the distance between the implant-abutment junction (IAJ) and the most coronal point of the bone-to-implant contact was measured on the mesial and distal sides using Micro-Measure software (Scalar). Measurements were calibrated on

each image using the distance between two consecutive threads of the implant as a reference (0.9 mm). These distances were used as an estimate of the extent of bone resorption.

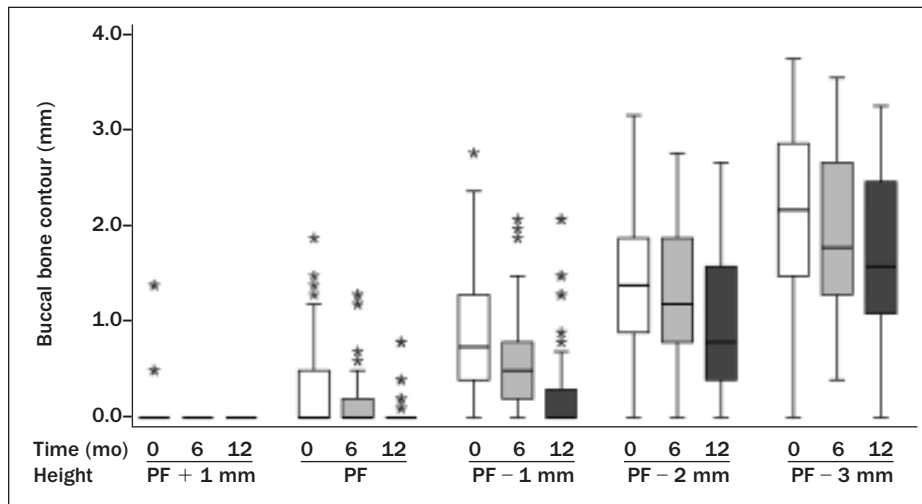
### Sample Size Calculation

Sample size was calculated to ensure adequate power for the comparison of baseline buccal bone contour between the groups with (bone-retaining group) and without (bone-loss group) bone wall at 1 year. In the authors' preliminary studies, standard deviations of buccal bone contour were found to be 0.6 to 0.8 mm. Differences between groups were estimated to be 0.6 mm.<sup>17</sup> The sample size was calculated to provide an 80% power with an  $\alpha$  of 0.05, and it was found to be 17 to 29 subjects per group. On the basis of these calculations, more than 60 participants were recruited in this study.

### Statistical Analysis

Linear regression analyses were used to examine differences between data obtained at two time points. Spearman correlation coefficient (two-tailed) was used to examine the relationship between changes in the vertical height of the buccal bone and recession of the buccal mucosa. To identify any association between initial contour and the fate of the buccal bone, subjects were divided into two groups at each height with respect to the presence of buccal bone at 1 year. Buccal bone contour at baseline was compared between the two groups using the Mann-Whitney *U* test. A *P* value of  $< .05$  was considered statistically significant. All statistical analyses were performed using PASW Statistics software version 18.0 (IBM).





**Fig 3** Lateral contour of the buccal bone at each height and time point. Distributions of data are shown using box plots. The median data are indicated by horizontal bars, the vertical bars indicate the range, the horizontal boundaries of the boxes represent the first and third quartiles, and the asterisks (\*) represent the outliers.

## RESULTS

A total of 66 dental implants were placed in 30 patients (26 women and 4 men; mean age,  $47.3 \pm 10.1$  years; range, 30 to 63 years). All participants were nonsmokers and were systemically healthy. Implants were placed in molar/premolar regions in the maxilla ( $n = 16$ ) or mandible ( $n = 50$ ). Twenty-eight implants (42.4%) were placed in a region that had remained edentulous for more than a year after tooth extraction. Of the remaining implants, 18 (27.3%) and 11 (16.7%) were placed after waiting periods of 6 to 12 months and less than 6 months, respectively, after extraction.

Just after implant insertion, the vertical height of the buccal bone was  $-0.14 \pm 0.86$  mm ( $n = 66$ ; range, +1.6 to  $-3.5$  mm). The mesial and distal bone heights were  $0.82 \pm 1.07$  mm and  $0.62 \pm 0.87$  mm, respectively.

After a healing period of 3 to 5 months, all implants showed an ISQ that was greater than 60, suggesting osseointegration of the implants. These were utilized for definitive restorations, and the superstructures were placed 6 months after surgery.

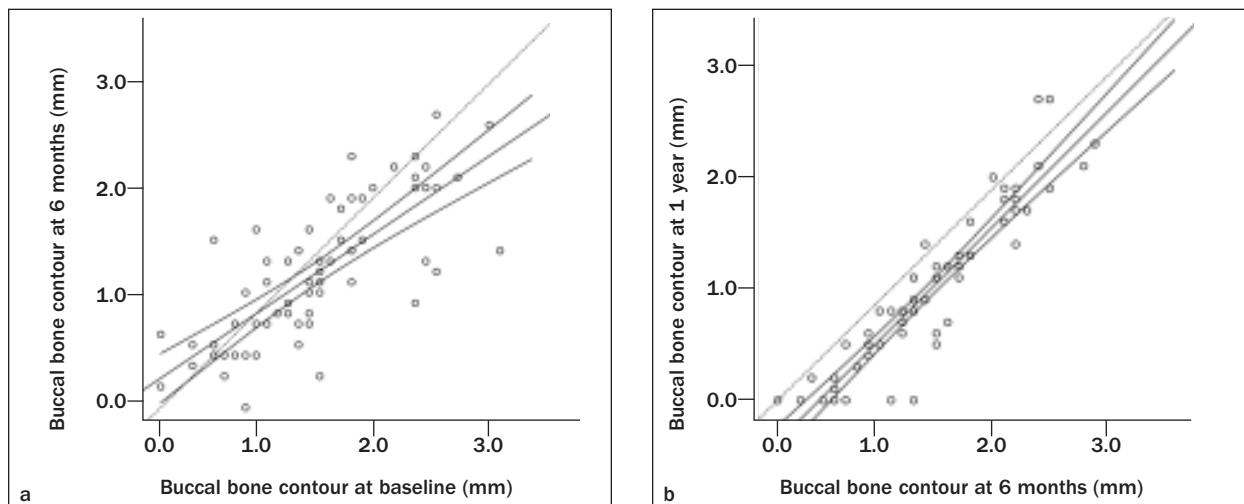
All patients completed the follow-up. There were no cases of implant rejection or severe complications. Implants fulfilled the criteria of success proposed by Albrektsson et al in 1986.<sup>11</sup> The implants exhibited a probing depth of  $2.7 \pm 0.6$  mm ( $n = 66$ ) on the buccal side. mPI and mGI scores were 0 for all implants, implying that the patients maintained a good level of marginal tissue hygiene throughout the study.<sup>18,20</sup>

### Lateral Contour and Vertical Height of Buccal Bone

Figure 3 shows the distribution of data pertaining to the lateral contour of the buccal bone at each height and time point. At the platform (0 mm) level, buccal bone was present in 37.9% of the participants at

baseline, and its contour decreased during the first 6 months after surgery. At 1 year, only 6.1% participants exhibited buccal bone walls. More apically, the median contour values during the study period decreased to 0.75, 0.60, and 0.60 mm at PF  $-1$  mm, PF  $-2$  mm, and PF  $-3$  mm, respectively. Figure 4 shows the differences in buccal bone contour at the PF  $-2$  mm level between the different time points. During the first 6 months after surgery (see Fig 4a), any buccal bone wall less than 1.5 mm thick maintained its contour; however, bone walls more than 2 mm thick tended to resorb slightly. In contrast, during the period from 6 months to 1 year (see Fig 4b), the buccal bone resorbed horizontally by approximately 0.4 mm, irrespective of its contour. There were no significant differences in the amount of horizontal bone resorption between the maxilla and mandible (Table 1). Similar tendencies were observed in data for the PF  $-1$  mm and PF  $-3$  mm levels (data not shown). Table 2 shows the number of participants with each category of vertical buccal bone height during the study period. The distribution of participants at baseline was almost unchanged at 6 months but changed noticeably at 1 year. Changes in heights ranged from 0 mm to  $-4$  mm, with a median change of  $-1$  mm during the final 6 months.

Table 3 shows a comparison of the buccal bone contour at baseline between the groups with (bone-retaining group) and without (bone-loss group) bone walls at each height at 1 year. The bone walls at baseline were thicker in the bone-retaining group than in the bone-loss group, and the difference was significant for the PF  $-1$  mm and PF  $-2$  mm levels ( $P = .002$ ). At 1 year, the median bone contour in the bone-retaining group was 0.55 mm and 1.10 mm at the PF  $-1$  mm and PF  $-2$  mm levels, respectively. This analysis was not performed for the PF  $+1$  mm or PF  $-3$  mm levels because of the lack of data in one group.



**Fig 4** Differences in buccal bone contour at the PF – 2 mm level (a) between the baseline and 6-month after surgery time points and (b) between the 6-month and 1-year after surgery time points. Regression lines and 95% confidence intervals are shown. Dotted lines indicate the  $y = x$  lines.

**Table 1 Comparison of Horizontal Bone Resorption Between the Maxilla and Mandible**

Implant position	Number of implants	Bone resorption at the PF – 2 mm level (mm)	
		Baseline to 6 months*	6 Months to 1 year*
Maxilla	16	$-0.27 \pm 0.53$	$-0.42 \pm 0.32$
Mandible	50	$-0.16 \pm 0.47$	$-0.33 \pm 0.24$

\*No significant difference between maxillary and mandibular values.

### Horizontal Thickness and Vertical Recession of Buccal Mucosa

Figure 5 shows the differences in horizontal thickness of the buccal mucosa at the PF – 2 mm level between the 6-month and 1-year time points. The horizontal thickness of the mucosa remained unchanged during the 1 year after surgery, independent of its initial thickness. The same results were obtained for the PF, PF – 1 mm, and PF – 3 mm levels (data not shown).

Vertical recession of the buccal mucosa during the period from 6 months to 1 year was  $0.39 \pm 0.14$  mm ( $n = 66$ ; range, 0.2–0.8 mm). There was no correlation between the change in buccal bone height and mucosal recession (Spearman  $\rho$ , 0.191;  $n = 66$ ;  $P = .124$ ).

### Radiographic Evaluation

At baseline, mesial and distal heights of bone-to-implant contact from IAJ were  $-0.3 \pm 0.5$  mm and  $-0.3 \pm 0.4$  mm, respectively ( $n = 66$ ). These heights decreased by an average of 0.9 mm at 6 months and decreased by a further 0.3 mm at 1 year. Mesial and distal bone heights at 1 year were  $-1.5 \pm 0.4$  mm and  $-1.5 \pm 0.4$  mm ( $n = 66$ ), respectively.

**Table 2 Vertical Height of the Buccal Bone: Distribution Comparison ( $n = 66$ )\***

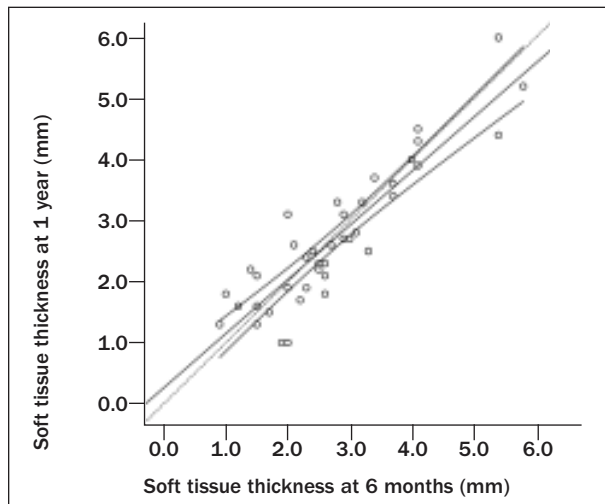
Vertical height (mm)	Number of subjects		
	Baseline	6 Months	1 Year
$\geq 1$	2	0	0
$\geq 0, < 1$	23	26	4
$\geq -1, < 0$	<b>35</b>	<b>32</b>	20
$\geq -2, < -1$	4	8	<b>32</b>
$\geq -3, < -2$	1	0	9
$< -3$	1	0	1

\*Median values are in bold.

**Table 3 Comparison of Buccal Bone Contour at Baseline Between Groups, Divided According to the Presence or Absence of Bone at Each Height at 1 Year**

Height	Bone walls	Number	Bone contour at baseline (mm)		P value
			Median	Range	
PF	Present	4	1.10	0.5 to 1.9	.18
	Lost	21	0.60	0.2 to 1.5	
PF – 1 mm	Present	22	1.30	0.2 to 2.8	.002*
	Lost	38	0.65	0.2 to 2.1	
PF – 2 mm	Present	53	1.50	0.5 to 3.2	.002*
	Lost	11	0.80	0.3 to 2.4	

\*Significant difference ( $P < .05$ ).



**Fig 5** Differences in buccal soft tissue thickness at the PF – 2 mm level between the 6-month and 1-year time points. Regression line and 95% confidence intervals are shown. Dotted line indicates the  $y = x$  line.

## DISCUSSION

In this study, the authors measured the buccal contour of peri-implant bone and mucosa at prescribed time points during 1 year after implant surgery using measuring instruments that they designed. To the best of the authors' knowledge, this is the first study to directly measure dimensional changes in the buccal bone and mucosa after surgery. The following findings were noted: the buccal bone exhibited horizontal resorption during the study period at all vertical heights measured; the most coronal point of the buccal marginal bone exhibited vertical resorption of approximately 1 mm during the final 6 months; thick buccal bone at baseline tended to persist, albeit with a decreased thickness, at 1 year; and the buccal mucosa exhibited recession of approximately 0.4 mm during the period from 6 months to 1 year.

The buccal bone at vertical heights 0 to 3 mm apical to the platform resorbed horizontally for 1 year. In addition, when assessed at each height, resorption was observed regardless of the initial contour of the buccal bone after surgery. These findings indicate that bone resorption occurred on the buccal surface and was not limited to the marginal area around the implants. The authors' findings suggest that the reformation of biologic width<sup>8,21</sup> is not the only cause of the observed bone resorption. Effects of flap surgery on bone homeostasis have been suggested in the literature.<sup>22–24</sup> This could be a cause of the buccal bone resorption observed in our study, while it is uncertain whether the effects of surgery persisted even after 6 months. Another possible interpretation may be the physiologic remodeling process of the edentulous alveolar ridge.

Buccal marginal bone resorbed vertically by approximately 1 mm during the period from 6 months to 1 year. However, marginal bone loss on the proximal sides was primarily observed during the 6 months after surgery, as reported in the literature.<sup>9,11,12</sup> This discrepancy in timing was probably due to differences in measuring points, bone-to-implant contacts on radiographs, and the most coronal point of the bone wall on direct measurements. In fact, proximal bone levels on baseline radiographs were 0.9 to 1.1 mm lower than those measured during surgery. If marginal bone loss could be associated with the platform level,<sup>21,25</sup> it is reasonable to assume that marginal bone would be evenly resorbed at the buccal side of the implants. These findings suggest that marginal bone resorption may have started on the implant surface without changes in the most coronal point of the buccal bone (baseline to 6 months) and that the point started to resorb later (6 months to 1 year). Initial contour and horizontal resorption of the buccal bone also played a potential role in this process.

The thick buccal bone present at baseline tended to persist at 1 year, albeit with a decreased thickness. Between the bone-retaining group and bone-loss group, the ranges of the initial contour almost overlapped, implying that there was no clear threshold of initial contour for determining the results. However, there was a significant difference between the median initial contour values between the two groups, suggesting that thick bone has the advantage of retaining the bone walls after treatment. If the median initial contour value in the bone-retaining group was used as a reference, a buccal bone contour of more than 1.5 mm at surgery would be preferable for retaining the bone wall after 1 year. Spray et al reported the influence of facial bone thickness at the first surgery of a two-stage protocol on the marginal bone response observed at the second surgery and proposed a critical thickness of 1.8 to 2.0 mm for maintaining bone thickness.<sup>17</sup> They did not assess the facial bone after surgery; however, the results of the current study suggest that bone with a thickness greater than the critical thickness may remain present with a slightly decreased thickness after treatment.

Dimensional changes in peri-implant tissue on the buccal side are clinically observed as vertical recession or growth of the marginal mucosa. The buccal bone resorbed vertically by approximately 1 mm during the 6 months after prosthetic treatment; however, recession of the marginal mucosa was approximately 0.4 mm over the same period; these measurements were not correlated. Benic et al<sup>13</sup> reported a similar discrepancy between the levels of marginal bone and mucosa around implants after 7 years of function. These findings suggest that other unknown factors affect the level of the marginal mucosa. However, buccal bone

loss may be a risk factor for recession in the long term because mucosa does not firmly integrate with the implant surface.

This study has two limitations. First, the participants were not evenly distributed with regard to age, sex, and implant location. These factors could have affected dimensional changes in the peri-implant tissue after surgery<sup>26</sup>; however, the authors were unable to include enough participants to assess the effects of these factors. Second, the study was a prospective cohort study, not a randomized controlled trial. The authors' results showed an association between the initial buccal bone contour and the fate of the bone; however, the association of unknown confounding factors could not be ruled out.

## CONCLUSIONS

Within the limits of the present prospective study, the results highlight the following:

1. Buccal bone resorbed on its surface by approximately 0.6 mm in the horizontal direction over 1 year after surgery.
2. Vertical height of the buccal bone decreased by approximately 1 mm during the period of 6 months to 1 year after surgery.
3. Thick buccal bone at baseline tended to persist at 1 year, albeit with a decreased thickness.
4. The buccal mucosa receded by approximately 0.4 mm over 6 months after prosthetic treatment, and it exhibited no correlation with buccal bone resorption.

## ACKNOWLEDGMENTS

The authors reported no conflicts of interest related to this study.

## REFERENCES

1. Schwartz-Arad D, Herzberg R, Levin L. Evaluation of long-term implant success. *J Periodontol* 2005;76:1623–1628.
2. Sorni-Bröker M, Peñarrocha-Diago M, Peñarrocha-Diago M. Factors that influence the position of the peri-implant soft tissues: A review. *Med Oral Patol Oral Cir Bucal* 2009;14:e475–479.
3. Esposito M, Hirsch JM, Lekholm U, Thomsen P. Biological factors contributing to failures of osseointegrated oral implants. (II). Etiopathogenesis. *Eur J Oral Sci* 1998;106:721–764.
4. Quirynen M, De Soete M, van Steenberghe D. Infectious risks for oral implants: A review of the literature. *Clin Oral Implants Res* 2002;13:1–19.
5. Araújo MG, Lindhe J. Dimensional ridge alterations following tooth extraction. An experimental study in the dog. *J Clin Periodontol* 2005;32:212–218.
6. Schropp L, Wenzel A, Kostopoulos L, Karring T. Bone healing and soft tissue contour changes following single-tooth extraction: A clinical and radiographic 12-month prospective study. *Int J Periodontics Restorative Dent* 2003;23:313–323.
7. Araújo MG, Lindhe J. Ridge alterations following tooth extraction with and without flap elevation: An experimental study in the dog. *Clin Oral Implants Res* 2009;20:545–549.
8. Oh TJ, Yoon J, Misch CE, Wang HL. The causes of early implant bone loss: Myth or science? *J Periodontol* 2002;73:322–333.
9. Astrand P, Engquist B, Dahlgren S, Gröndahl K, Engquist E, Feldmann H. Astra Tech and Brånemark system implants: A 5-year prospective study of marginal bone reactions. *Clin Oral Implants Res* 2004;15:413–420.
10. Grunder U, Gracis S, Capelli M. Influence of the 3-D bone-to-implant relationship on esthetics. *Int J Periodontics Restorative Dent* 2005;25:113–119.
11. Albrektsson T, Zarb G, Worthington P, Eriksson AR. The long-term efficacy of currently used dental implants: A review and proposed criteria of success. *Int J Oral Maxillofac Implants* 1986;1:11–25.
12. Davarpanah M, Martinez H, Celletti R, Alcoforado G, Tecucianu JF, Etienne D. Osseotite implant: 3-year prospective multicenter evaluation. *Clin Implant Dent Relat Res* 2001;3:111–118.
13. Benic GI, Mokti M, Chen CJ, Weber HP, Hämmerle CH, Gallucci GO. Dimensions of buccal bone and mucosa at immediately placed implants after 7 years: A clinical and cone beam computed tomography study. *Clin Oral Implants Res* 2012;23:560–466.
14. Miyamoto Y, Obama T. Dental cone beam computed tomography analyses of postoperative labial bone thickness in maxillary anterior implants: comparing immediate and delayed implant placement. *Int J Periodontics Restorative Dent* 2011;31:215–225.
15. Schliephake H, Wichmann M, Donnerstag F, Vogt S. Imaging of periimplant bone levels of implants with buccal bone defects. *Clin Oral Implants Res* 2003;14:193–200.
16. Schulze RK, Berndt D, d'Hoedt B. On cone-beam computed tomography artifacts induced by titanium implants. *Clin Oral Implants Res* 2010;21:100–107.
17. Spray JR, Black CG, Morris HF, Ochi S. The influence of bone thickness on facial marginal bone response: Stage 1 placement through stage 2 uncovering. *Ann Periodontol* 2000;5:119–128.
18. Fransson C, Wennström J, Berglundh T. Clinical characteristics at implants with a history of progressive bone loss. *Clin Oral Implants Res* 2008;19:142–147.
19. Tarnow DP, Cho SC, Wallace SS. The effect of inter-implant distance on the height of inter-implant bone crest. *J Periodontol* 2000;71:546–549.
20. Mombelli A, van Oosten MA, Schurch E Jr, Land NP. The microbiota associated with successful or failing osseointegrated titanium implants. *Oral Microbiol Immunol* 1987;2:145–151.
21. Berglundh T, Lindhe J. Dimension of the periimplant mucosa. Biological width revisited. *J Clin Periodontol* 1996;23:971–973.
22. Job S, Bhat V, Naidu EM. In vivo evaluation of crestal bone heights following implant placement with 'flapless' and 'with-flap' techniques in sites of immediately loaded implants. *Indian J Dent Res* 2008;19:320–325.
23. Blanco J, Nuñez V, Aracil L, Muñoz F, Ramos I. Ridge alterations following immediate implant placement in the dog: Flap versus flapless surgery. *J Clin Periodontol* 2008;35:640–648.
24. Jensen OT, Cullum DR, Baer D. Marginal bone stability using 3 different flap approaches for alveolar split expansion for dental implants: A 1-year clinical study. *J Oral Maxillofac Surg* 2009;67:1921–1930.
25. Brogginini N, McManus LM, Hermann JS, et al. Peri-implant inflammation defined by the implant-abutment interface. *J Dent Res* 2006;85:473–478.
26. Bengazi F, Wennström JL, Lekholm U. Recession of the soft tissue margin at oral implants. A 2-year longitudinal prospective study. *Clin Oral Implants Res* 1996;7:303–310.